

# Croton Oil Peels

Richard H. Bensimon, MD

This author discusses the utility and versatility of the modern croton oil peel, which, unlike older formulations, may be used for all ages and skin types for effective and long-lasting skin resurfacing. He provides the rationale for various croton oil concentrations, focusing on avoiding complications while achieving a desirable clinical result and includes a comprehensive guide to application, appropriate formulas, and the perioperative process. Of significance is that this is a procedure with a distinct learning curve; the goal for the experienced practitioner is to control the application process, proceeding slowly enough to be able to stop at the appropriate depth. (*Aesthetic Surg J* 2008;28:33–45.)

The Baker-Gordon peel has been the standard in facial resurfacing since the early 1960s<sup>1</sup> and, although it gave dramatic results, the potential for hypopigmentation and a “waxy” porcelain look limited the use of the peel to more severe cases in older, light-eyed individuals. Moreover, the immediately irreversible nature of the application required a lot of faith and courage as the skin deeply frosted. This lack of control and the reputed cardiac toxicity proved too intimidating for most surgeons.

More recently, CO<sub>2</sub> lasers have been used for skin resurfacing, and although this is a viable alternative, hypopigmentation and a prolonged recovery with long-standing erythema remain real problems. The presumed advantage of the CO<sub>2</sub> laser is the precision of depth of damage, but more and more one hears of practitioners abandoning the CO<sub>2</sub> laser.

There are now a multitude of lasers, including erbium, combination lasers, and fractionated laser, which may have their place, but at some point it becomes financially impractical to own multiple machines.

In 2000, Hetter<sup>2-5</sup> published a series of articles in which he analyzed the Baker-Gordon phenol peel and provided invaluable information to further the art and science of chemical peeling. Among his findings were that a weaker concentration of phenol did not peel deeper, as has been widely believed for decades. Hetter's<sup>2-5</sup> most valuable contribution was that he convincingly proved that croton oil was the critical peeling agent and not phenol. Furthermore, an analysis of the Baker-Gordon formula showed that the croton oil concentration was quite high at 2.1%, responsible for both the results and the drawbacks. Armed with this information, Hetter<sup>2-5</sup> lowered the concentration of phenol and varied the concentration of the

croton oil. This may seem like a small difference, but it fundamentally changed the peel and has ushered in a new era in chemical peeling. This new formulation was in essence a Baker-Gordon peel without a problematic concentration of croton oil, making it an effective and versatile peel applicable to all ages and skin types.

A major advantage, indeed the key to the peel as conceived by Hetter,<sup>2-5</sup> is that the croton oil concentration used is weak enough so that the application technique can be altered to affect the depth reached. The “all-or-none” phenomenon seen in the Baker-Gordon peel was simply that the croton oil concentration was so high that it immediately resulted in dense frosting. This gave the surgeon little leeway, consistently resulting in deep peeling and the well-known problems of hypopigmentation.

The capability of varying the croton oil concentration gives the surgeon the freedom to choose the appropriate depth of the peel depending on skin type, age, or clinical need. Along with choice of concentration, how the peel is actually applied is the main determinant of depth reached. In contrast to the traditional Baker-Gordon peel, now the surgeon is in precise control of the process.

The practical ramifications are profound: It is now feasible to obtain the desired clinical result without peeling to a depth that causes troublesome hypopigmentation. Concentration choice also allows the surgeon to use different strengths on different areas of the face depending on relative skin thickness. An obvious application of this concept is peeling of the eyelids, where a weak concentration (0.1%) can very effectively and safely improve this delicate skin, while the traditional peel (croton oil concentration of 2.1%) carried the risk of scarring or ectropion.

## PRE-PEEL PREPARATION

The success of the peel begins in adequately preparing the patient. Patients must be motivated and have a long-

Dr. Bensimon is in private practice in Trumbull, CT.

**Table 1.** Hetter peel formulas with a 35% phenol vehicle

	Croton oil				
	0.2%	0.4%	0.8%	1.2%	1.6%
Water	5.5 mL	5.5 mL	5.5 mL	5.5 mL	5.5 mL
Septisol	0.5 mL	0.5 mL	0.5 mL	0.5 mL	0.5 mL
USP phenol 88%	3.5 mL	3.0 mL	2.0 mL	1.0 mL	0.0 mL
Stock solution containing phenol and croton oil (see below)	0.5 mL	1.0 mL	2.0 mL	3.0 mL	4.0 mL
Total	10 mL	10 mL	10 mL	10 mL	10 mL

0.1% = 1 mL of 0.4% + 1.2 mL phenol + 1.8 mL water.

0.05% = 1 mL of 0.2% + 1.2 mL phenol + 1.8 mL water.

Stock solution = 24 mL phenol + 1 mL croton oil (0.04 mL croton oil/1 mL stock solution or 4% croton oil).

term perspective. The reward is a dramatic and long-term improvement in skin texture, which I believe is not obtainable by any other modality.

A strong emphasis is placed on the postpeel phase so that patients know what to expect. I routinely show photographs of the day-by-day recovery and make an effort to include any family member or caregiver. I arrange for prospective patients to speak or ideally meet with other patients who have had a comparable peel. Seeing someone in person who has had a good result is an invaluable tool to demonstrate that the difficult recovery is worth it. I have found that the peel is well tolerated if the patient is well informed.

The best way to ensure success and prevent complications such as pigmentary changes is to adequately prepare the skin before the peel by applying aggressive doses of tretinoin, hydroquinone, phytic acid, or glycolic acid. The main ingredients are tretinoin and hydroquinone 4%, but we believe that using the complete Obagi Nu-Derm system (Skin Specialists PC, Omaha, NE) as preparation is valuable. The epidermis is stabilized, the dermis is stimulated to increase collagen content, and the melanocytes are suppressed. The purpose of this process is to regulate cell function and reduce the risk of postoperative alteration of pigment.

The preparation begins 4 to 6 weeks before peeling with tretinoin 0.1%, 1 inch (= 1 g) applied over the whole face once per day. The application should be extended to the earlobes, tragus, and hairline and continued to 1 inch below the mandibular border and 1 to 2 mm below the ciliary edge. Avoid the upper lids because this can lead to irritation. If the neck is to be peeled, the same preparation is used, decreasing the frequency if the skin is irritated.

Hydroquinone 4% is applied twice daily. The purpose is to suppress and regulate melanocytes to prevent postinflammatory hyperpigmentation. Glycolic acid 8% or phytic acid 2% is applied once daily to help accelerate exfoliation by loosening desquamated cells in the stratum corneum.

This regimen results in erythematous, flaky skin that the patient must accept as a normal effect. The preparation process should be stopped 4 to 5 days before the peel to allow settling of the epidermis. Skipping or short-

ening the preparation has resulted in intense and excessively long erythema.

## MEDICATIONS

The possibility of a herpetic outbreak is real and antiviral prophylaxis is routinely used. Valacyclovir hydrochloride 500 mg, one tablet administered 2 times daily is begun 3 days before the procedure and continued for 1 week after peeling. Narcotic pain medication is prescribed for postpeel discomfort. If properly managed, the peel should not be overly painful. Ibuprofen 800 mg administered three times daily is recommended along with a Medrol Dosepak (Mova Pharmaceutical, Manati, PR) beginning the day after the peel. Most patients are “bothered” rather than in pain, therefore a sleep medication can be useful.

## PREPARATION OF THE SOLUTION

The preparation of the peeling solution is a critical step that should be performed by the operating surgeon or entrusted to someone intimately acquainted with the process. The ingredients are readily available, inexpensive, and the same as in the classic Baker-Gordon peel, including water, phenol, croton oil, and Septisol (Vestal Laboratories, St. Louis, MO). Old formulations used drops of croton oil, which can be awkward to deal with and can lead to variability. The process is simplified by use of a stock solution consisting of United States Pharmacopeia (USP) 88%, phenol 24 mL, and croton oil 1 mL. This solution yields a concentration of .04 mL croton oil/1 mL stock solution. By increasing the volume of the ingredients, they are measured easily and accurately with standard syringes. By varying the relative volumes of phenol and stock solution, different croton oil concentrations are possible with standard tables (Table 1). As an example, to make a 0.8% croton oil solution, one would mix water 5.5 mL, Septisol 0.5 mL, and add USP phenol 88% 2 mL and stock solution 2 mL. These 2 mL of stock solution contain croton oil 0.08 mL. Because the total volume of the solution is 10 mL, the final concentration is

0.08 mL of croton oil in 10 mL total volume or 0.8%. To make weaker concentrations such as 0.1% and 0.05%, one first makes 0.4% and 0.2%, and these are further diluted as denoted on the table. The final concentration of phenol with all of these formulas is always 35% by volume. The stock solution, at 4% croton oil, is always meant to be diluted and should never be applied to the skin full strength.

### INTRAOPERATIVE ROUTINE

The peel is quite stimulating, therefore intravenous sedation or general anesthesia may be necessary. Adequate pain control is imperative to provide a pain-free emergence from anesthesia and a comfortable early post-peel course. If the initial pain cycle is avoided, the entire recovery and overall experience will be better. Standard local nerve blocks are performed with bupivacaine with epinephrine (Marcaine + Epi) along with subcutaneous infiltration of dilute plain bupivacaine (Marcaine) throughout the operative site. Omitting these steps even on a light peel will result in impressive discomfort immediately after peeling. Intramuscular ketorolac tromethamine is administered as an adjunct to anesthesia unless an operative procedure is being performed at the same time. Intraoperative steroids are given and are followed by a Medrol Dosepak the next day.

Ophthalmic ointment and corneal protectors are not used because phenol may dissolve in the ointment, preventing adequate and immediate flushing out should it become necessary. Extreme care around the eyes at all times is essential.

The fear of cardiac complications has long been associated with the phenol peels, but deaths caused by the peels are anecdotal, and it is difficult to isolate phenol toxicity as a cause. Arrhythmias in the course of peeling are well documented, although rare.<sup>6,7</sup> There is a suggestion that the cause may be the intense stimulation brought about by a high concentration of croton oil.<sup>8,9</sup> With lower concentration of croton oil, lower concentration of phenol (35% vs 49%), and careful attention to local anesthesia of the face, cardiac complications have not been seen. Baker<sup>10</sup> (personal communication, 2006) has stated that in the very large number of peels he has performed with the original formula, he has never encountered cardiac arrhythmias needing treatment. Prudent precautions include cardiac monitoring, adequate hydration, and performing a full-face peel in no less than 45 minutes. The skin is thoroughly degreased with acetone to allow even absorption. The patient should be told not to apply anything on the skin on the morning of the peel.

### APPLICATION

The different concentrations are placed in separate, easily identifiable bowls or cups. The applying materials are 2 x 2 gauze and cotton-tipped applicators. This gauze is

dipped into the solution and carefully wrung out. The mixture is stirred before each application. An assistant helps dry the applying hand to prevent inadvertent application where it is not wanted. One must exercise constant vigilance in this respect.

With the damp gauze in hand, observing the color change of the skin, multiple rubbings are made. The acid coagulates and precipitates the protein, forming a *frost*, which is a way of describing varying degrees of a white appearance. As the application progresses, the depth is gauged by the degree of frosting, which becomes progressively more dense (Figure 1). The speed of the appearance of the frost depends on the concentration used and how wet the gauze is. With the typical concentrations described and using damp gauze, the appearance of the frost is gradual and can be seen in 10 to 20 seconds. Unlike peels with trichloroacetic acid (TCA), there is no need to wait several minutes to see the final depth.

### FACTORS THAT INFLUENCE DEPTH OF PEEL

There are a number of variables that determine the depth of the peel. As was elegantly demonstrated by Hetter,<sup>2-5</sup> the concentration of croton oil is a key determinant of depth reached and may be the dividing line between an excellent result and hypopigmentation. Regardless of the concentration used, the number of coats applied has an additive effect. With this in mind, even a weak concentration can lead to deep involvement, even scarring. The safety of a weak concentration is only relative and should not be taken for granted.

As previously mentioned, the croton oil concentrations are relatively weak so that the application technique is the other main factor of the depth reached. A damp sponge can be rubbed multiple times, variable pressure can be used, or the gauze can be wetter and fewer passes can be made. Theoretically, the same depth can be reached by using different techniques or even different concentrations.

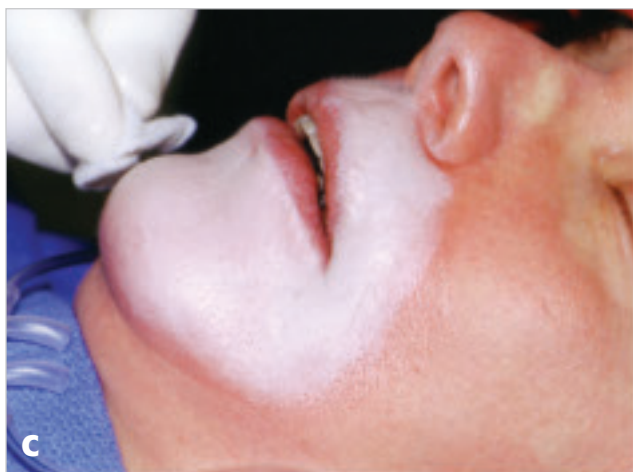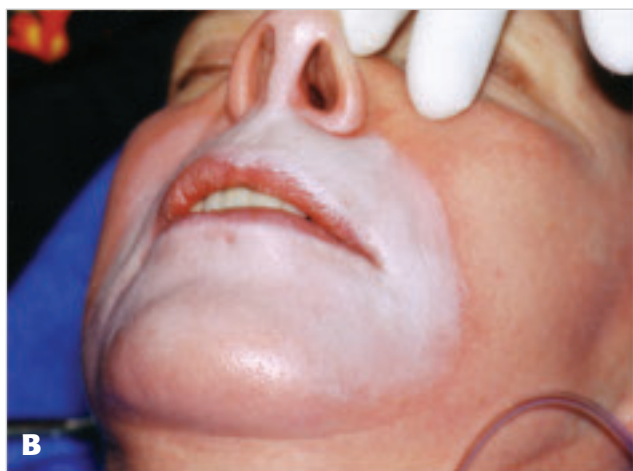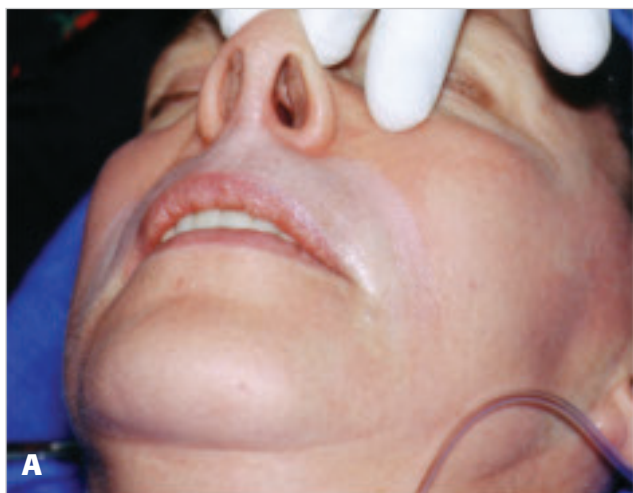The location on the face where the peel is applied is significant because of the relative thickness or resilience of the skin. For example, the perioral skin can sustain a deeper peel than delicate skin in the eyelids.

### ASSESSING DEPTH OF THE PEEL

Finding the endpoint is the key to any resurfacing technique. This depends on the degree of frosting, which is visually determined, based on experience, and therefore subjective. Anatomically, a superficial peel wounds all the structures of the epidermis. Generally speaking, croton oil peels affect change beyond the epidermis. A medium-depth peel goes to the papillary dermis. Deep peels go to the reticular dermis (upper to mid), and peeling to the lower reticular dermis is likely to cause scarring.

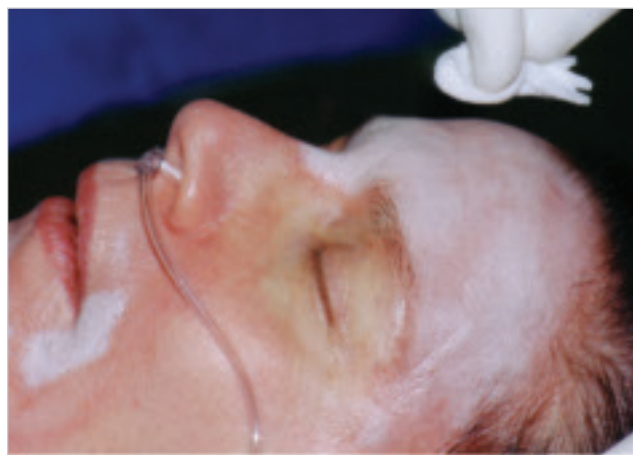The visual clues are as follow: A thin, transparent frost with a pinkish background denotes a peel to the papillary dermis. A solid, thick, organized frost is the upper to mid



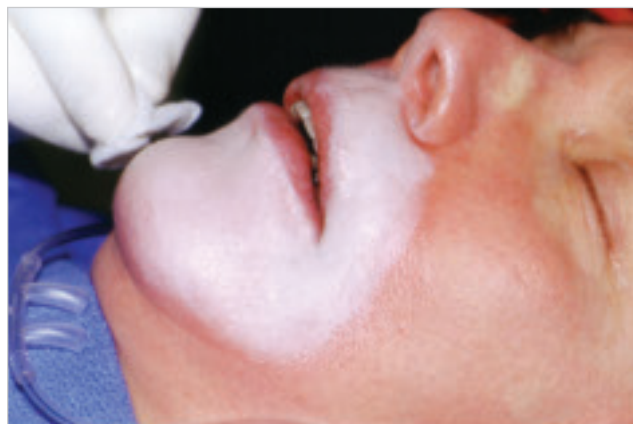

**Figure 1. A-C,** As multiple rubbings are made the frost becomes more dense and opaque.

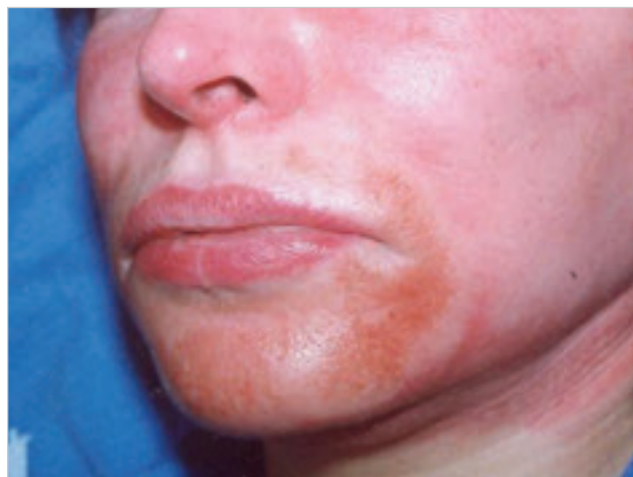reticular dermis. A thick, gray-white sheet of frost with eventual red-brown overtones is the mid dermis and as deep as the peel should go (Figures 2 to 4). Practitioners familiar with the different degrees of frosting with TCA peels will have little difficulty transitioning to croton oil peels.<sup>11</sup> *The important concept is that this is a gradual continuum and the experienced practitioner is able to control*



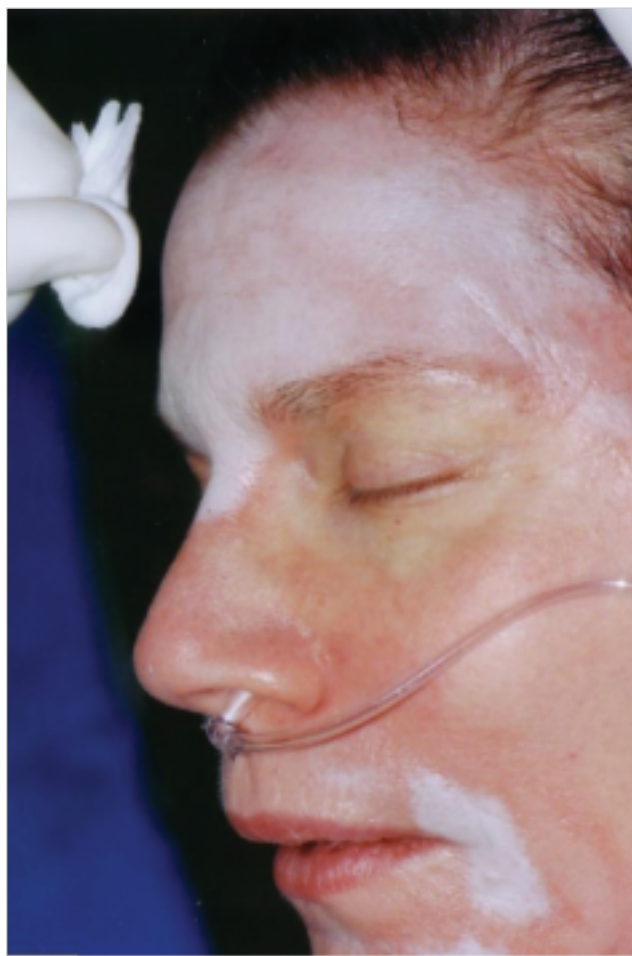**Figure 2.** The frost on the lateral forehead and temporal area is transparent with a pink background; this represents peeling to the papillary dermis. In contrast, the frost in the glabellar area is more organized, denoting deeper peeling.



**Figure 3.** Solid, dense, opaque, even frost indicates reaching the upper to midreticular dermis.



**Figure 4.** A sustained red-brown overtone as the frost disappears is indicative of peeling to the midreticular dermis. The peel can be extended to the vermillion, and the commissures respond well to deep peeling.



**Figure 5.** The cheeks and forehead are peeled with 0.4%, usually to the papillary dermis (thinner white frost with pinkish background). The glabella and central forehead are thicker and can be peeled to the reticular dermis (solid white frost).

*the process and go slowly enough to be able to stop at the appropriate depth and go no deeper.*

Another assessment tool for evaluating the level of peel is epidermal sliding, which is seen when the peel reaches the level of the papillary dermis and the epidermis is separated from the underlying reticular dermis and slides as a thin, independent sheet.

This sliding disappears when the peel advances to the immediate reticular dermis and the epidermis and dermis bond together, forming a single protein block. Epidermal sliding is particularly valuable when peeling eyelid skin; it is not obvious in thick-skinned areas, such as around the mouth, but it is more evident in the forehead and especially in the eyelids. *Defrosting* or loss of the frost can also be used to assess the peel depth, although it is already after the fact (Table 2).

## GENERAL PEEL RECOMMENDATIONS

The following are general recommendations that are frequently applicable, but it is important to consider individual variations and to constantly judge the depth of the

peel (Table 3). The perioral area (including the lower nose) is quite resilient and can withstand a strong concentration such as 0.8%. This is extended beyond the chin onto the mental crease. The rhytids are stretched out to allow even and complete penetration. The peel can be extended into the vermillion to improve lip wrinkles and gain much appreciated lip eversion (Figure 7). The commissures heal well and can be peeled relatively deep.

The cheeks and forehead are peeled with 0.4% concentration. The glabellar area and central forehead are relatively thick and can be peeled to the mid-dermis (solid white frost). The lateral forehead and temporal area are more delicate and peeling to the papillary dermis may be more appropriate (white frost with pinkish background) (Figure 5). The peel does not damage hair follicles; therefore it is extended to the hairline and brows to avoid lines of demarcation. Deep peeling in the cheeks is not often needed. Caution should be exercised in the preauricular area and geniomandibular groove.

The eyelids are peeled with 0.1% and 0.05% may be a consideration for the upper lid. In the lower lid, the peel is extended close to the ciliary margin. The peel is applied with a cotton-tipped applicator and as indicated, the relative dampness and the number of passes affect the depth. Although these are weak concentrations, the delicate eyelid skin responds well and in a predictable fashion. Epidermal sliding and an even white frost are easily recognizable findings that denote the proper depth (Figure 6). Usually the upper lids are peeled to the tarsal fold only to prevent tight lids. If there is obviously laxity below the tarsal fold, peeling can be considered, perhaps with a weaker concentration, such as 0.05%.

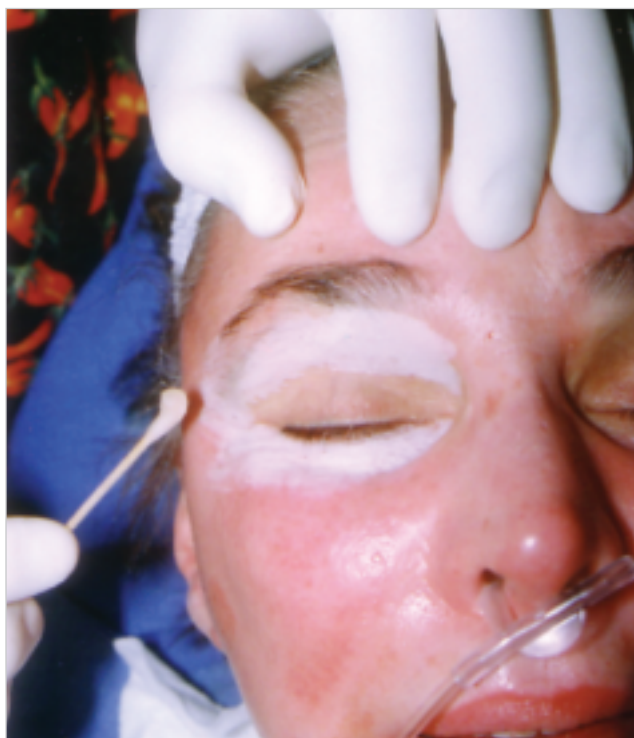The peel is extended onto the neck, using 0.1% in a judicious manner with light strokes because this skin is thinner and does not have the recuperative potential of the face. The goal is a light, wispy frost that is not at all organized. Being able to safely peel the neck is important because the obvious demarcation along the mandible seen with lasers or deeper peels is avoided. The purpose of the neck peel is to prevent demarcation and not to improve wrinkles.

Precise deeper peeling of individual rhytids is possible without affecting surrounding areas. This can be done with a wetter cotton-tipped applicator painting the individual line and then quickly drying it as a dense frost appears (Figure 7). Small areas or more

**Table 2.** Defrosting times

Papillary dermis	5-10 minutes
Upper-mid dermis	15-20 minutes
Mid-lower dermis	20-30 minutes





**Figure 6.** The eyelids are peeled with 0.1% and 0.05% to accommodate the upper lid. Despite these weak concentrations, the eyelids respond well and predictably.

precise application can be done with the wooden end. This specificity of treatment is a great advantage of particular value in the perioral area where it is often needed most.

One suggestion when first starting out is to keep the maximum concentration at 0.4%, keeping the

overall depth more superficial with the thought of re-peeling, should it become necessary. Focal re-peeling of persistent rhytids is easy to do with the patient under local anesthesia. If there appears to be uneven peeling or if there is a sharp demarcation between areas peeled with different concentrations, then a weak concentration such as 0.2% or 0.1% is used to overpeel or blend these sectors.

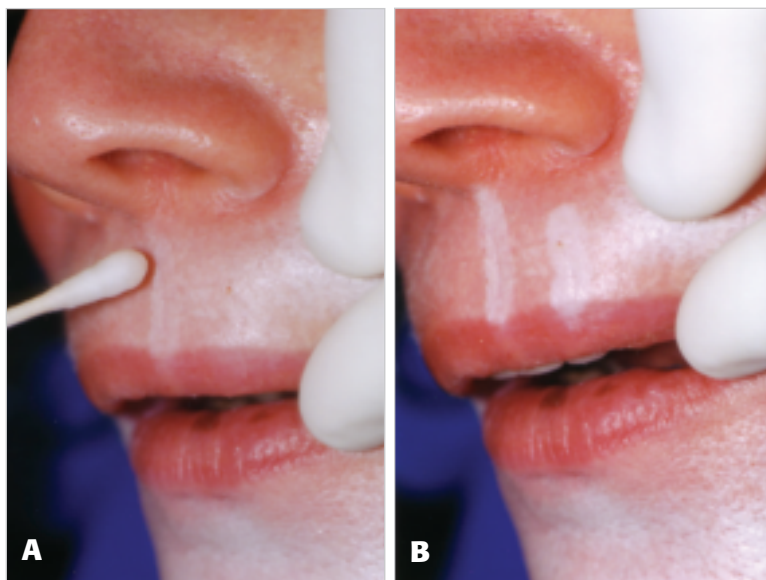
### POSTPEEL CARE

Once the peel is completed, wait for all the frosting to subside. Mix one tube of Polysporin (Pfizer, New York, NY) and one tube of lidocaine jelly and briskly beat them into an even emulsification. This antibiotic/anesthetic cream is applied over all the peeled areas.

The remainder of the mixture is placed in a container and given to the patient. The purpose is to moisturize the peeled skin to prevent crusting and to provide analgesia. An advantage of this approach is that the wound is always in view for evaluation.

The early phase of the recovery lasts 7 to 10 days as the skin gradually reepithelializes. Deeper peels may require 14 days. During this period, the skin is moist and oozing serous fluid. Constant application of the ointment is necessary to prevent drying and crusting. The patient is strongly admonished not to pick or dislodge any crusts to prevent scar formation.

The appearance of the patient on the first day can be quite impressive. Depending on the depth of the peel, the patient may be considerably swollen and generally unrecognizable. Despite this, most patients are not uncomfortable. The appearance gradually improves, and the skin is healed by 2 weeks (Figure 8). The next phase of the recovery is notable for ery-

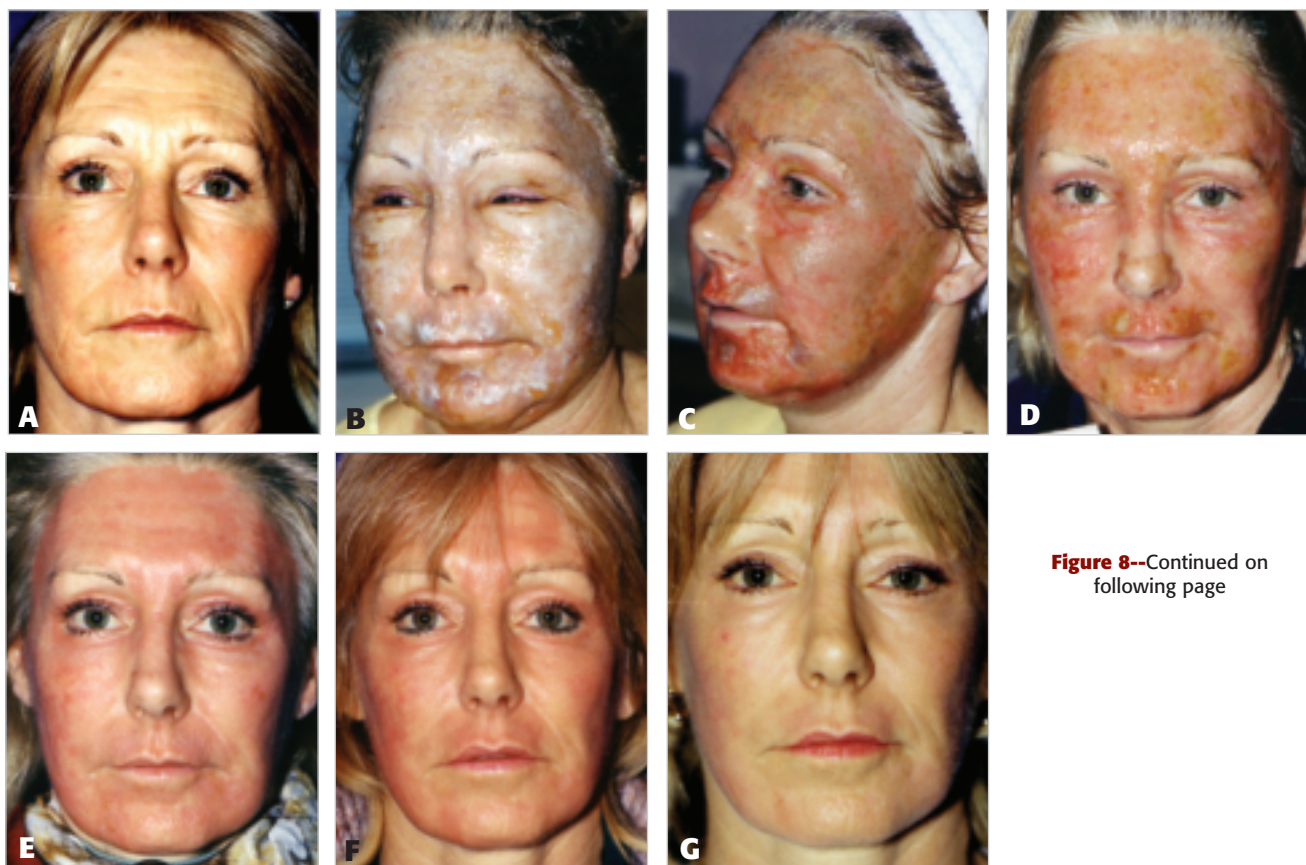

**Figure 7. A, B,** Precise deeper peeling of individual rhytids is achieved with a wetter applicator and quick drying as dense frost appears. This specificity is very useful in the perioral area.

**Table 3.** General peel recommendations\*

Location	Croton oil concentration
Forehead, temporal area	0.2%-0.4%. The glabellar area can be peeled deeper than lateral forehead and temporal area. Precise deeper peeling of individual lines is possible with a wetter cotton-tipped applicator and blotting dry as frost appears.
Perioral area (including lower nose)	0.4%-0.8%. Precise deeper peeling of individual lip lines is useful.
Cheeks, preauricular area	0.2%-0.4%. Deep peeling is rarely needed.
Eyelids	0.1% lower eyelids 0.1%. 0.1 upper eyelids. Consider 0.05% in upper lids, especially below tarsal fold.
Neck	0.1%. This is light peeling for blending of color and not for improvement of wrinkles.

\*Predictable problem areas that require careful attention include the temporal area, the immediate preauricular area, the geniomandibular area, and the medial upper lid where it abuts with the nasal skin. The above are general recommendations. The key to the peel is to always judge the depth by the visual clues described, whatever technique or concentration is used. There is only relative safety in using a weaker concentration, and similar depths can be reached by use of different techniques, even different concentrations.



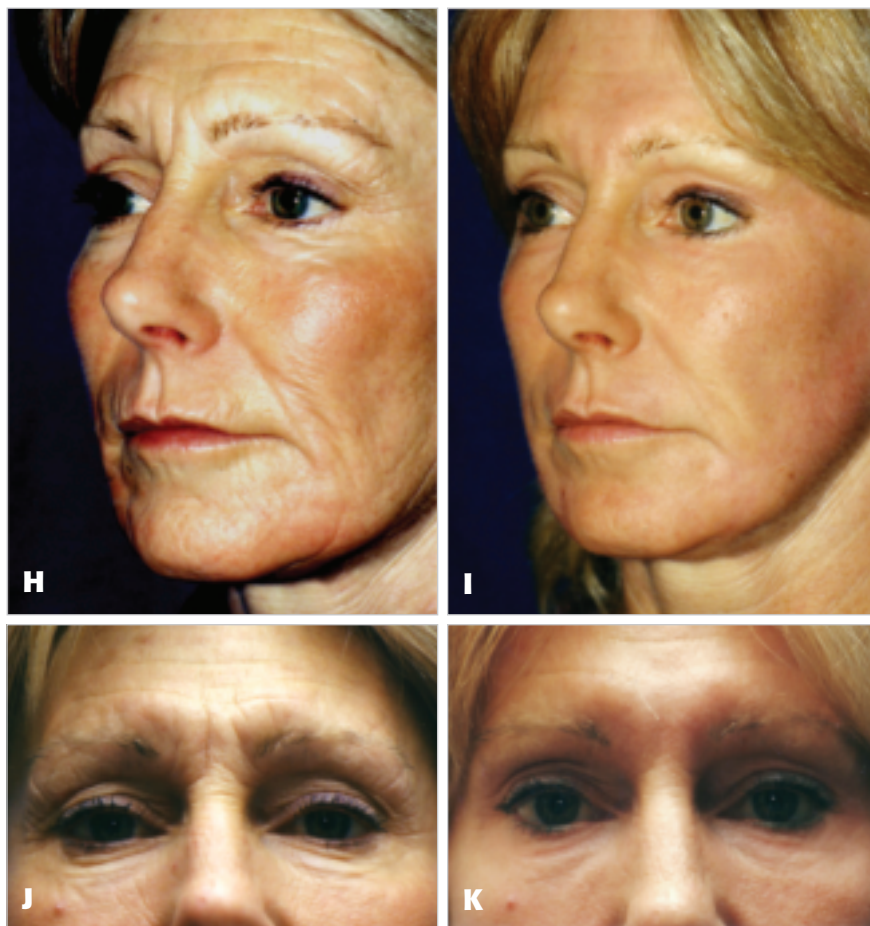**Figure 8**--Continued on following page

**Figure 8.** **A**, Preoperative view of a 49-year-old woman with advanced wrinkling, sun damage, and smoker's lines. **B**, Day 1 postpeel with anesthetic/antibiotic ointment applied. There is serous oozing and some blistering along the neck. Despite their appearance, patients are usually not uncomfortable. **C**, Day 3 postpeel. Gradual reepithelialization is under way. Note obvious underpeeling along brows and lower nose. **D**, Day 5 postpeel. **E**, Day 7 postpeel. Epithelialization is complete and patient may wear makeup. Beginning of erythema phase. **F**, Four weeks postpeel. Erythema remains, but is beginning to blend. **G**, Fourteen weeks postpeel. Depending on depth of peel and skin type, erythema predictably lasts between 8 and 12 weeks.

thema, which predictably lasts between 8 to 12 weeks and is usually well tolerated with camouflage makeup. Intense erythema can be seen with deeper peels and can be improved with judicious short-term use of topical steroids.

### VARIATION OF PEELS

Segmental peels are possible but carry the risk that there will be a mismatch in coloration, therefore good judgment must be exercised. An individual with widespread solar damage carries a risk of demarcation,



**Figure 8**—Continued from previous page. **H**, Pretreatment view. **I**, Posttreatment view after 8 months. Note general tightening and marked improvement of deep lines in perioral and forehead area. **J**, Pretreatment. **K**, Posttreatment view after 1 year. Photos are taken with bounce flash to provide more accurate rendition of skin texture.

therefore a full face peel is preferable. Segmental perioral peels can be done, peeling to a medium depth at most. The color takes 8 to 10 weeks to blend adequately. Successful peeling in the mustache area alone is also possible in selected individuals.

An excellent location for segmental peeling is the eyelids. Lower eyelid skin in particular responds very well to a low croton oil concentration such as 0.1%. When peeled appropriately, the thin eyelid skin contained within the borders of the orbital rim is very forgiving, and healing is well tolerated and easily camouflaged with makeup or glasses. Another advantage of the lower eyelid peel is that it can easily be done with the patient under local anesthesia and in a gradual fashion. If a patient requests a quicker recovery, a lighter peel can be done and repeated in the future with additive effect. The lower eyelid can ultimately be peeled to the patient's satisfaction.

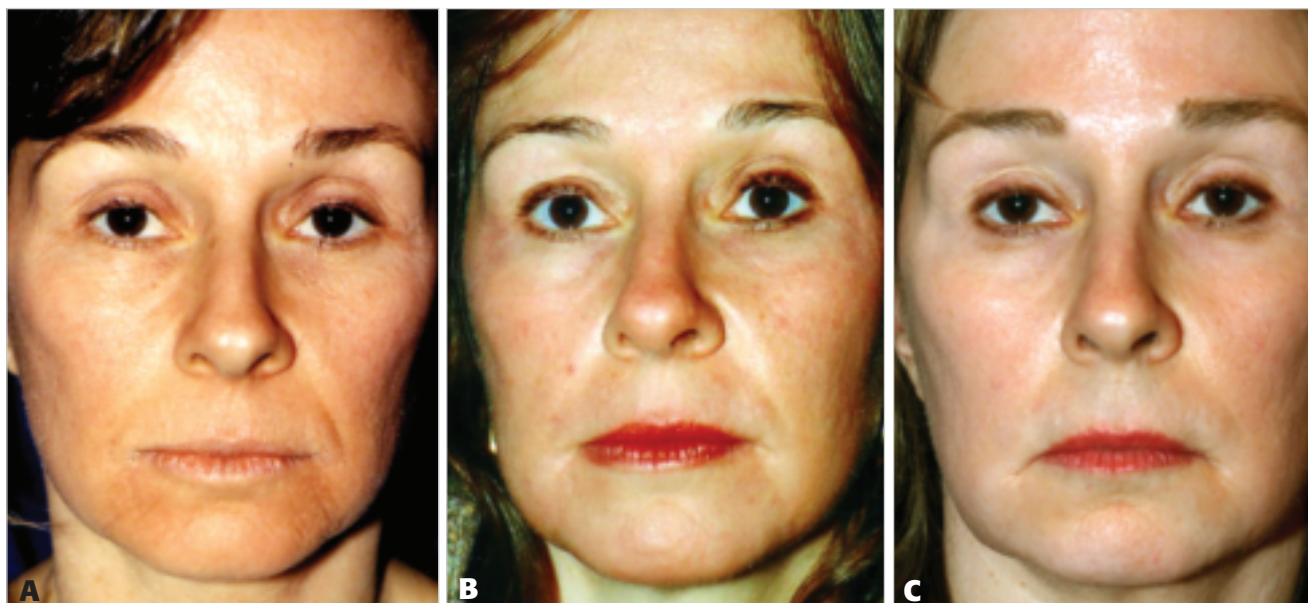
A very common unfavorable result in plastic surgery is ectropion or rounding of the lateral canthus after traditional lower lid blepharoplasty. These sometimes terrible complications stem from the mistaken belief that wrinkles and textural changes in the lid can be

improved by pulling the skin tight and removing the excess. When this is coupled with scarring in the middle lamella from an anterior approach, the result is an alteration in the shape of the outer canthus at best or frank ectropion at worst.

A better alternative is to address the structural issues (pseudoherniation of the orbital fat) through a transconjunctival approach, addressing the textural changes (which are rarely caused by excess skin) by peeling the skin. If improvement of the anterior lamella requires resection of true excess of skin or manipulation of the orbicularis oculi muscle, peeling of the skin can be done at a later time. This results in a true anatomic correction without disrupting the middle lamella. This is one of the best applications of the Hetter peel and is a good starting point for those who are reluctant to begin with a full face peel.

A novel use of these peels is to perform a lighter peel in younger individuals to improve mild imperfections while having an easier recovery (Figure 9). It was speculated that performing these light peels at a frequency of approximately 5 years would be necessary, but now with 7 years experience to date, I have yet to see a loss of effect. This





**Figure 9.** A, Pretreatment view of a 45-year-old woman with generalized elastosis and *etching* of the chin. B, Posttreatment view after 1 year. C, Posttreatment view after 6 years.

could be an excellent adjunct to many facial procedures except procedures in which major skin flaps are elevated, such as in a face lift. The general concentration of the peel is 0.2% or 0.4%, except for the lids and neck.

### ADVERSE RESULTS

Complications from croton oil peels are the same as with any deep resurfacing technique. The main complications, scarring and hypopigmentation, are operator dependent and are largely preventable by controlling the depth of peel. In 75 peels, patient response has been overwhelmingly positive. In 2 instances, there was delayed healing and thickening in small areas of the neck and temporal area. This is clearly evidence of peeling to the deep reticular dermis. Although disconcerting, this thickening or mild scarring responds well to injections of triamcinolone acetonide 10 mg/mL and 5-fluorouracil (off-label use) in a ratio of 3:2 or 4:2 and eventually fades away.

Hypopigmentation can occur if the peel penetrates deep enough. For individuals with pronounced rhytids, adequate improvement may necessitate peeling to a depth that will result in hypopigmentation. In most instances, the improvement is worth it, and in my experience, the porcelain look of the skin typical of older peels is not seen.

Hyperpigmentation may be seen during the recovery period. It is transient and responds well to tretinoin and hydroquinone 4%. Sun protection is important in preventing hyperpigmentation, and permanent problems have not been seen. Segmental hyperpigmentation and demarcation was seen in the

upper lip in one patient in whom the vermillion border was peeled more deeply without adequately blending with the skin closer to the nose.

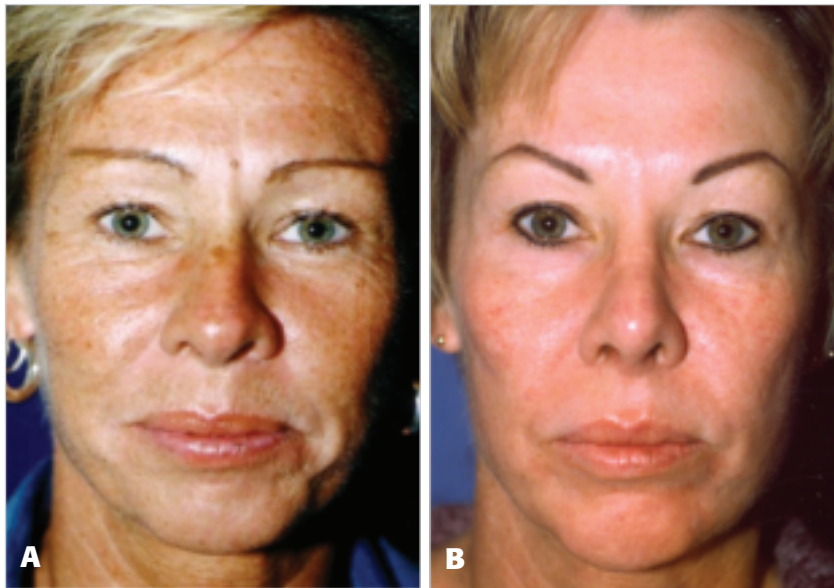Herpes simplex can be seen and is usually heralded by dysesthesia or intense itching. Treatment includes doubling the dose of oral antiviral therapy and adding topical antiviral, which should be applied with a cotton-tipped applicator to prevent spreading the infection. A herpes breakout occurred in one case, and although impressive, it did not leave any permanent sequelae.

Ectropion can result from injudicious peeling of the lower lids. As with blepharoplasty, caution should be exercised in patients with lid laxity. Sequential lighter peeling and temporary suspension of the lower lid are helpful in preventing this problem. I have seen only mild tension in the lower lid, which responded promptly to massage.

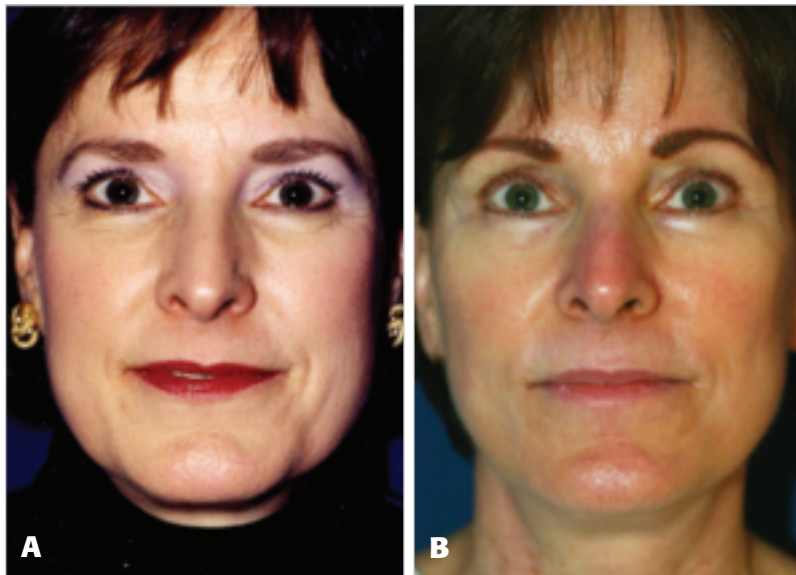
Milia can be seen very early in the healing process and responds to tretinoin or gentle excision with a fine needle. Prolonged erythema (greater than 12 weeks) has been seen only when the skin preparation was not done or was shortened.

### CLINICAL IMPRESSIONS

A concrete way to judge the validity of a cosmetic procedure is the longevity of results. A constant observation of the Baker-Gordon peel is the extremely long-lasting (if not permanent) results. Indeed, multiple histologic studies have shown the deposition of a substantial layer of collagen in the dermis that is aligned in an orderly manner and is believed to be the mechanism for the effacement of wrinkles.<sup>12-14</sup> This layer remains constant for years, even decades.



**Figure 10.** **A**, Preoperative view of a 47-year-old woman with severe sun damage and smokers' lines. **B**, Posttreatment view after 4 years.

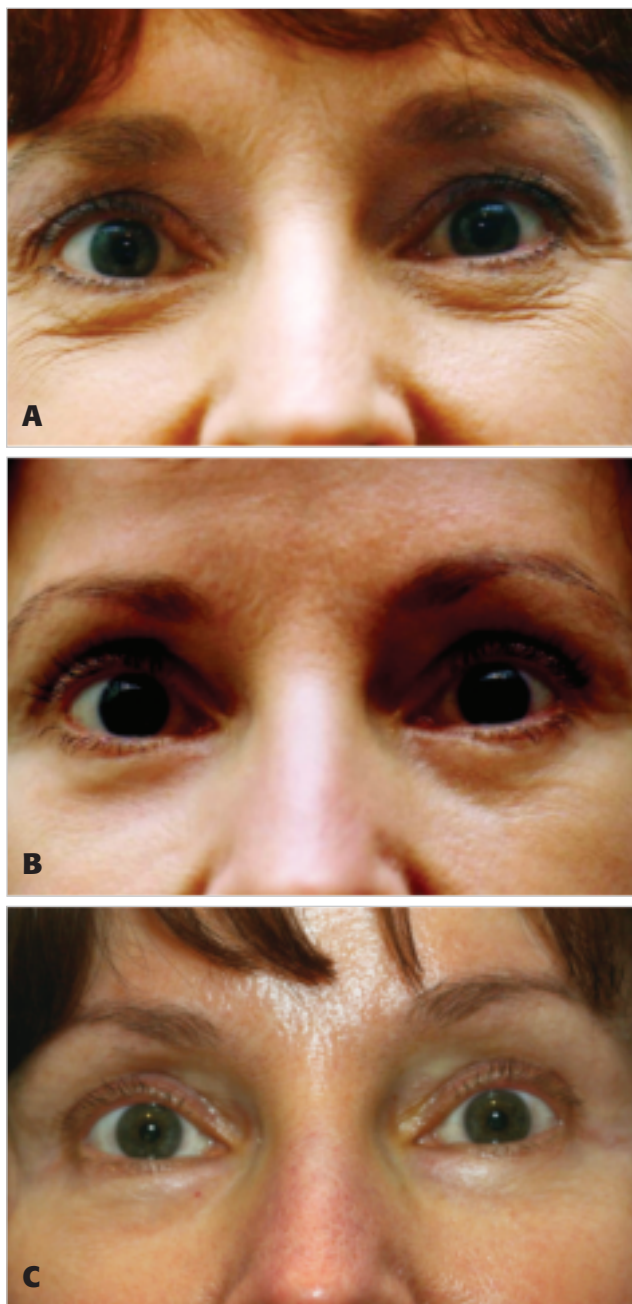

**Figure 11.** **A**, Preoperative view of a 53-year-old woman. **B**, Postoperative view at age 59, 4 years postpeel and face lift, endoscopic brow lift, and upper and lower blepharoplasty.

To date, clinical results with the Hetter peel show remarkable improvement in deep wrinkles and actinic damage without depigmentation. With 7 years experience now, the improvements seen are completely stable, and rather than showing diminishing results, the skin appears to improve with time (Figures 10–12). Although not yet proven by histologic studies, it is reasonable to expect that this stability is modulated by similar cellular changes occurring in the dermis, while not disrupting the function of melanocytes, as was the case with older peels. The fact

that repeated peels give additive effects suggests more deposition of collagen each time. The skin looks younger, because in essence, younger skin is being created.

Histologic studies have also shown eradication of actinic keratoses in deeply peeled skin.<sup>13,14</sup> The anecdotal impression of experienced practitioners is that those who have undergone peels do not have development of facial basal cell cancer or squamous cell cancer.<sup>10</sup> Indeed, in a recent study in the dermatology literature, Hantash et al<sup>15</sup> showed that laser resurfacing, fluorouracil, and 35% TCA



**Figure 12.** **A**, Pretreatment view of a 52-year-old woman. **B**, Post-treatment view after 1 year. **C**, Posttreatment view after 4 years.

peels were equally effective in keeping susceptible individuals free of nonmelanoma cancers for the studied 5-year period. The deeper croton oil peels are expected to have similar or better effect, further expanding the benefits and utility of this approach.

Many patients consider the textural changes of aging to be as important as their structural changes. We have many advanced surgical techniques to deal with the gravitational changes, but as plastic surgeons we are well aware that surgery can only indirectly improve textural issues and has little or no effect on the perioral area where it is frequently

needed most (Figures 13 and 14). With the croton oil peel, we at last have a powerful and effective tool to improve textural changes to complement surgery and realize the goal of truly comprehensive facial rejuvenation (Figure 15).

## CONCLUSION

The concepts of modern croton oil peels are quite simple. A stronger concentration of phenol penetrates more deeply than a weaker one, refuting what has been believed for decades. Croton oil is the critical peeling agent, and a high concentration of phenol is not needed to obtain a desired peel.

The “all-or-none” phenomenon attributed to the Baker-Gordon peel is simply that the croton oil concentration is so high that the operator has little control over the application process. By lowering the concentration of phenol and varying the concentration of croton oil, application technique and concentration choice now become the main factors that determine the depth of the peel. In this manner, the main complications of the Baker-Gordon peel can be avoided while still providing the desired clinical result. It is this fundamental difference that makes the Hetter peel such a powerful tool.

With multiple concentrations of croton oil available, the surgeon has great control and specificity. It is this fact that makes this peel available to any age group or skin type. Precise deeper peeling can be done on problem rhytids without adversely affecting other sectors of the face. Weaker concentrations can be used to great advantage on delicate eyelid skin. This can have a profound effect on the efficacy of lower lid blepharoplasties.

Inevitably, this peel will be compared with lasers, and some differences become immediately evident. The logistical ease of application and general availability of ingredients speak for themselves. The utility of this peel in the neck and the lack of a demarcation line at the mandible are important improvements. The reported greater deposition of collagen with deep peels may result in a qualitative difference when compared with other modalities that reach the same depth of damage. This is evidenced by the impressive longevity of the results. The results may or may not be comparable, but one difference is undebatable: The cost of lasers is substantial, whereas the cost of the peel is insignificant. With this in mind, lasers would have to be significantly better to recommend them. The choice is up to the individual practitioner. ▀

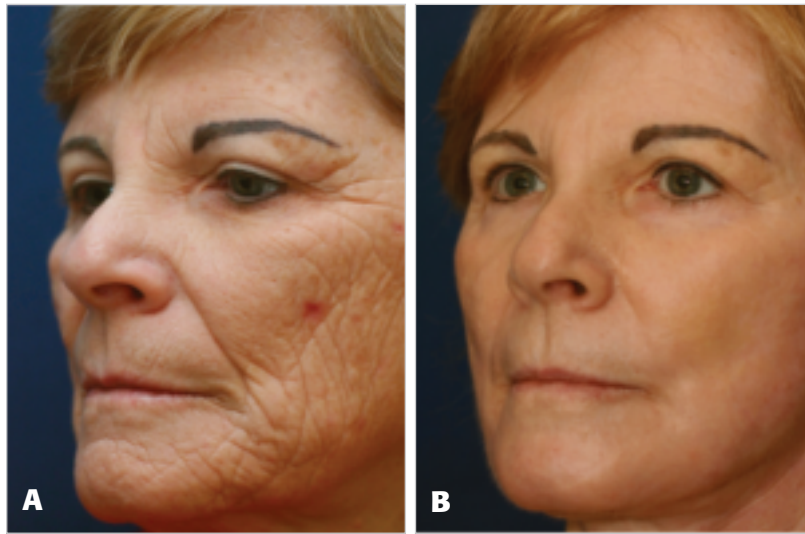## ACKNOWLEDGMENT

*The author would like to express his gratitude to Gregory Hetter MD, innovator, mentor and friend, whose ability to recognize the obvious is the very definition of genius.*

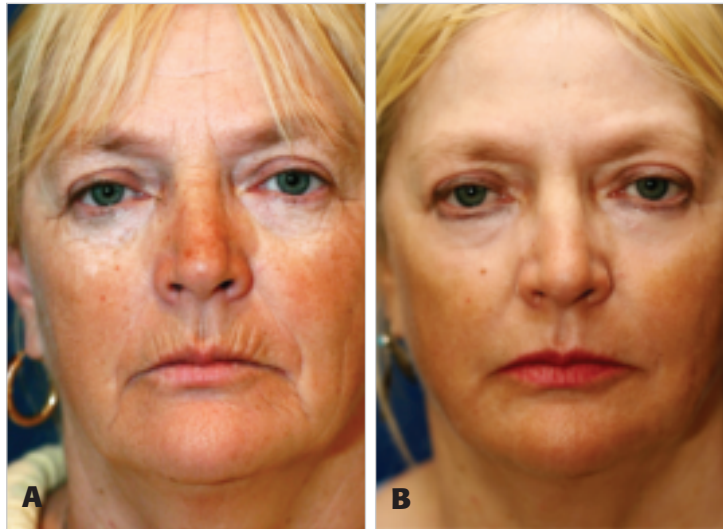## DISCLOSURES

*The author has no disclosures with respect to this article.*

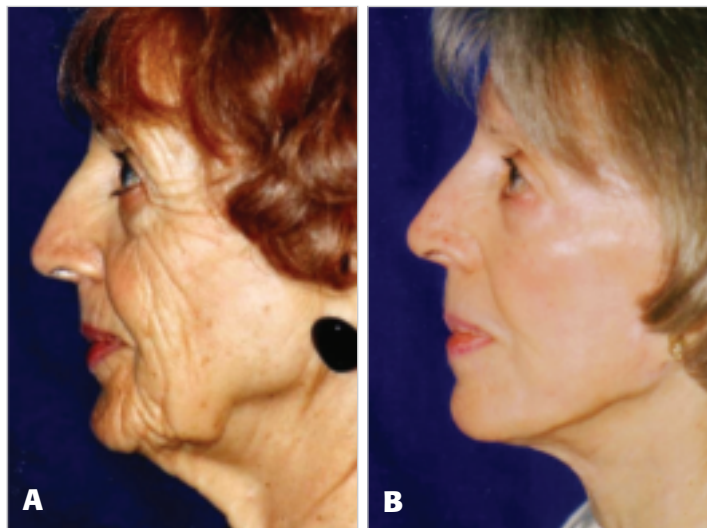



**Figure 13.** **A**, Pretreatment view of a 61-year-old woman. **B**, Posttreatment view after 1 year. Despite deep peel, she retains normal appearing pigment. (Bounce flash photo)



**Figure 14.** **A**, Pretreatment view of a 59-year-old woman. **B**, Posttreatment view after 1 year. Significant improvement, especially around mouth. (Bounce flash photo)



**Figure 15.** **A**, Preoperative view of a 75-year-old woman. **B**, Postoperative view at age 81, 5 years after face lift and 1 year postpeel. Comprehensive facial rejuvenation in which surgery corrected the structural aspect of aging and the peel corrected the textural issues.

## REFERENCES

1. Baker TJ. Chemical face peeling and rhytidectomy: a combined approach for facial rejuvenation. *Plast Reconstr Surg* 1962;29:199–207.
2. Hetter GP. An examination of the phenol-croton oil peel: part I. Dissecting the formula. *Plast Reconstr Surg* 2000;105:227–239.
3. Hetter GP. An examination of the phenol-croton oil peel: Part II. The lay peelers and their croton oil formulas. *Plast Reconstr Surg* 2000;105:240–248.
4. Hetter GP. An examination of the phenol-croton oil peel: part III. The plastic surgeon's role. *Plast Reconstr Surg* 2000; 105: 752–763.
5. Hetter GP. An examination of the phenol-croton oil peel: Part IV. Face peel results with different concentrations of phenol and croton oil. *Plast Reconstr Surg* 2000;105:1061–1083.
6. Truppmann ES, Ellenby JD. Major electrocardiographic changes during chemical face peeling. *Plast Reconstr Surg* 1979;63: 44–48.
7. Landau M. Cardiac complications in deep chemical peels. *Dermatol Surg* 2007;33:190–193.
8. Stagnone JJ, Stagnone GJ. A second look at chemabrasion. *J Dermatol Surg Oncol* 1982;8:701–705.
9. Edison RB. Lighter phenol peels allow faster recovery and less discomfort. *Aesthetic Surg Q* 1996;16:239–240.
10. Baker TJ. Is the phenol-croton oil peel safe? *Plast Reconstr Surg* 2003;112:353–354.
11. Obagi ZE. Endpoints. In: Obagi skin health restoration and rejuvenation. New York, NY; Springer- Verlag; 2000: 203–211.
12. Stegman SJ. A comparative histologic study of the effects of three peeling agents and dermabrasion on normal and sun-damaged skin. *Aesthetic Plast Surg* 1982;6:123–135.
13. Kligman AM, Baker TJ, Gordon HL. Long term histologic follow-up of the phenol face peels. *Plast Reconstr Surg* 1985;75:652–659.
14. De Rossi-Fattaccioli D. Histologic comparison between deep chemical peels (modified Litton's formulae) and extreme pulsed laser CO<sub>2</sub> resurfacing. *Dermatol Peru* 2005;15:181–184.
15. Hantash BM, Stewart DB, Cooper ZA, Rehms WE, Koch RJ, Swetter SM. Facial resurfacing for non-melanoma skin cancer prophylaxis. *Arch Dermatol* 2006;142:976–982.

---

Accepted for publication September 7, 2007.

Reprint requests: Richard H. Bensimon, MD, 5520 Park Ave., Suite 307, Trumbull, CT 06611.

Copyright © 2008 by The American Society for Aesthetic Plastic Surgery, Inc. 1090-820X/\$34.00

doi:10.1016.j.asj.2007.10.10.005

---